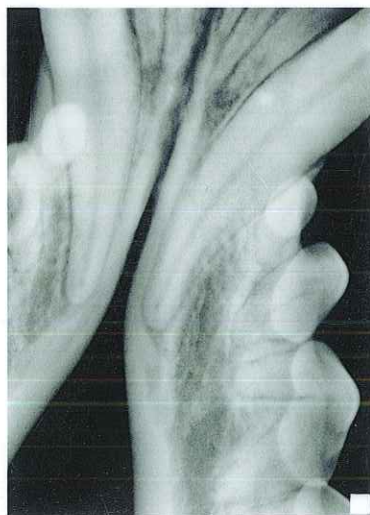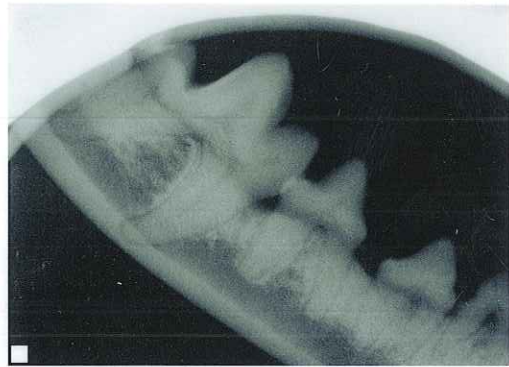
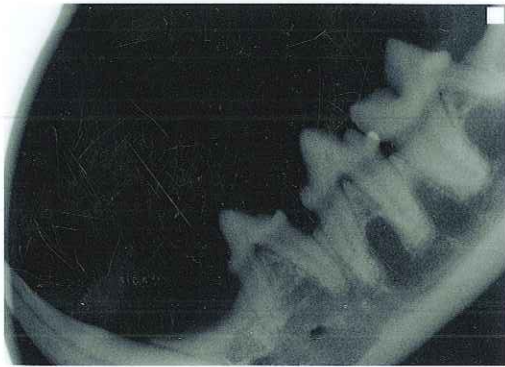
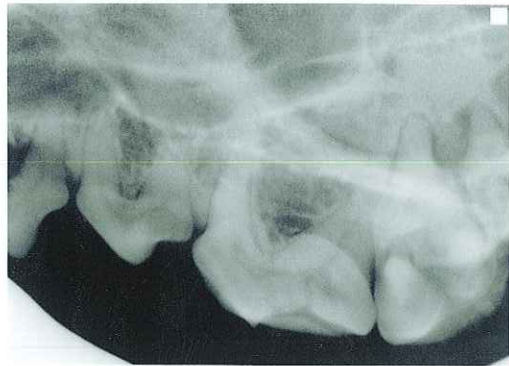
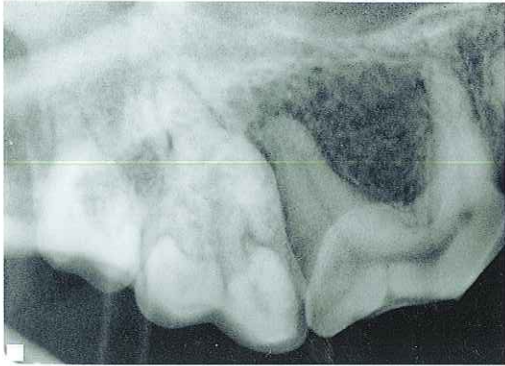
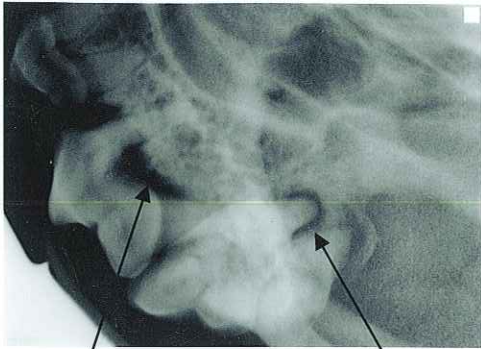


Normal X-Rays

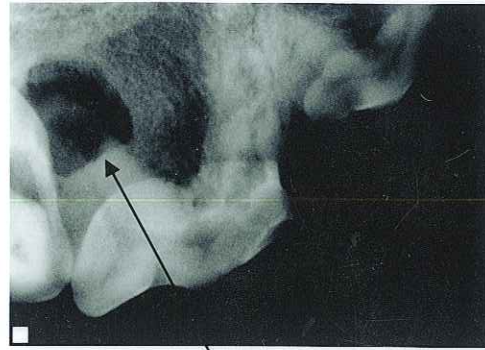


Tooth Root Abscess

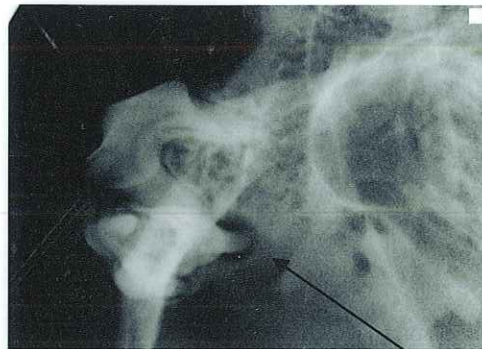


Bone Loss

Abscess

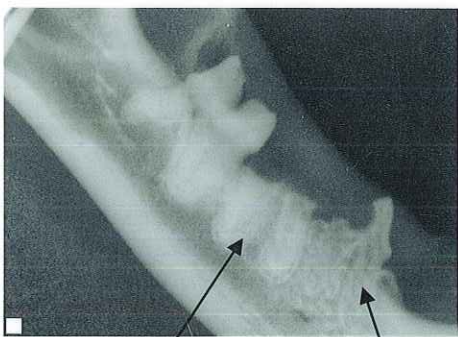

Abscess



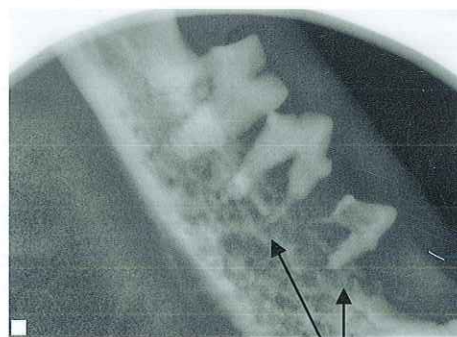
Abscess

Resorptive Lesion



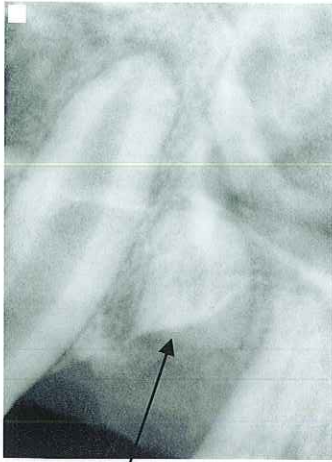
Missing Crown

Root Resorption

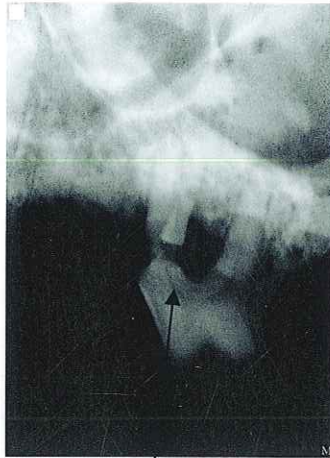


Root Resorption,  
Severe Bone Loss

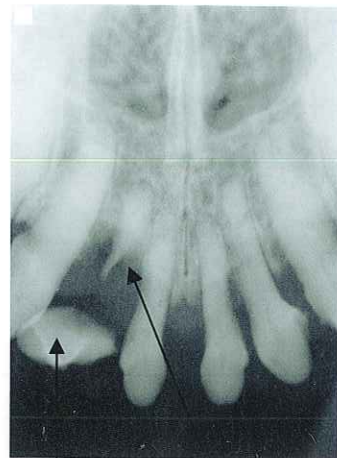
## Broken Tooth



Tooth Root Remnant

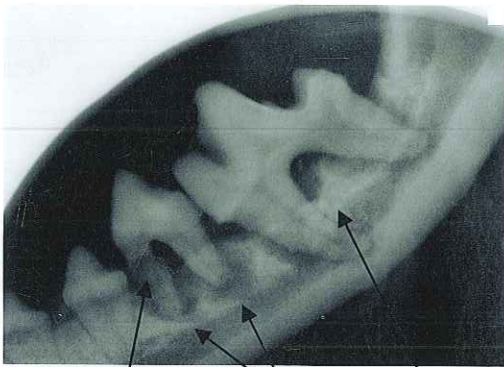


Broken Root



Crown

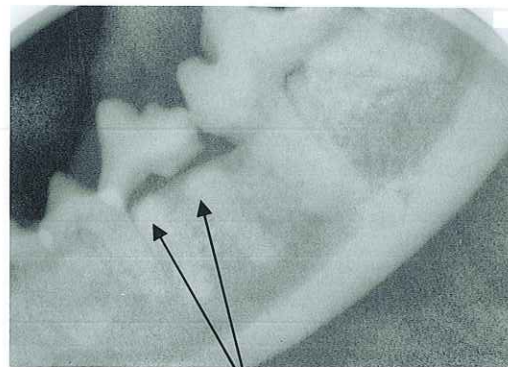
Root Remnant



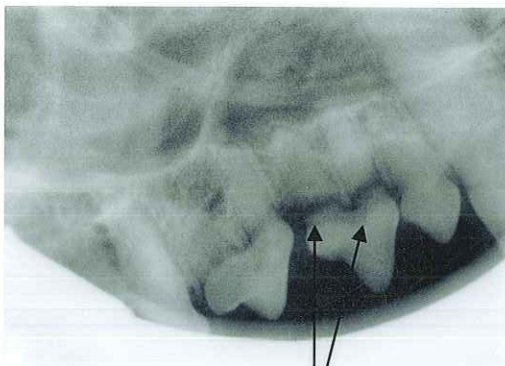
Broken Root

Abscess

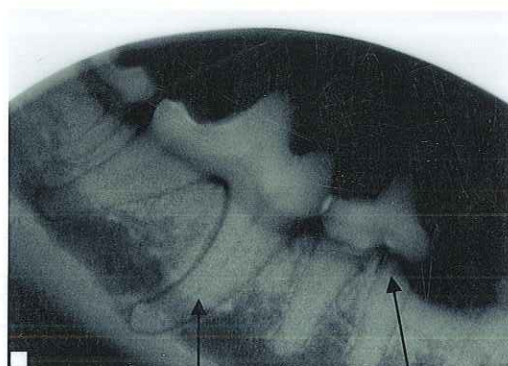
Bone Loss



Broken Crown



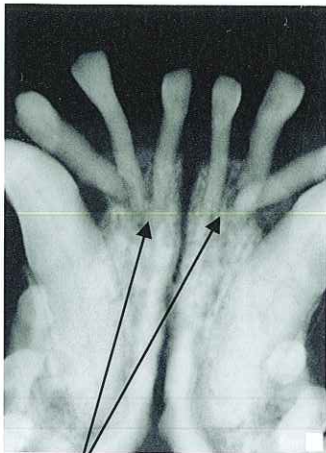
Broken Crown



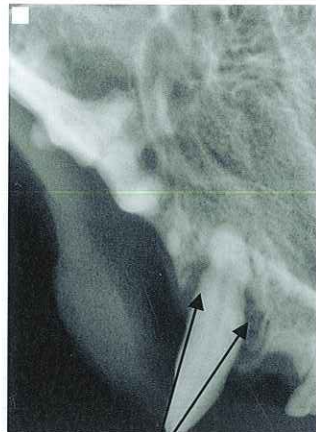
Curved Root

Broken Crown

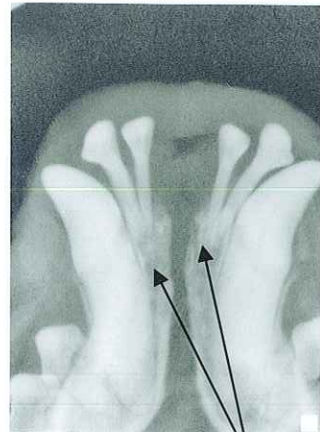
Bone Loss



Bone Loss

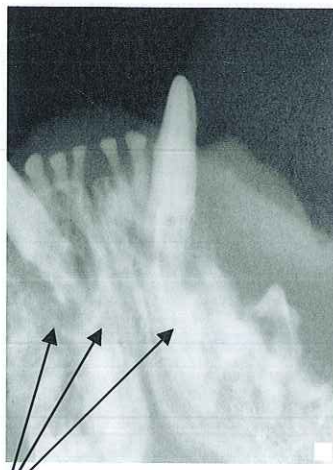


Bone Loss

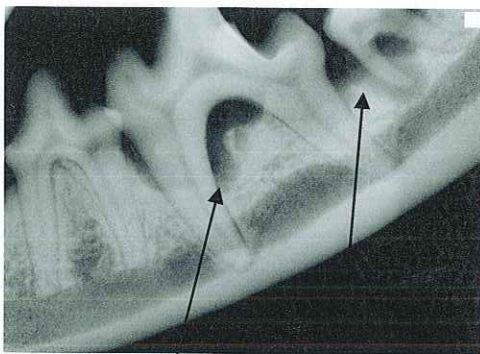
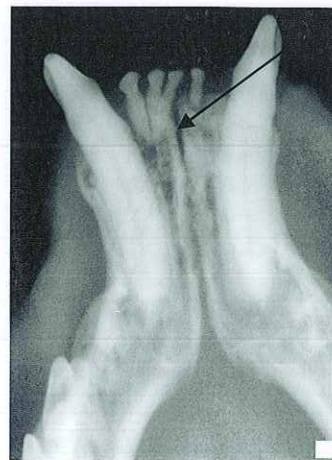

Bone Loss

Bone Loss

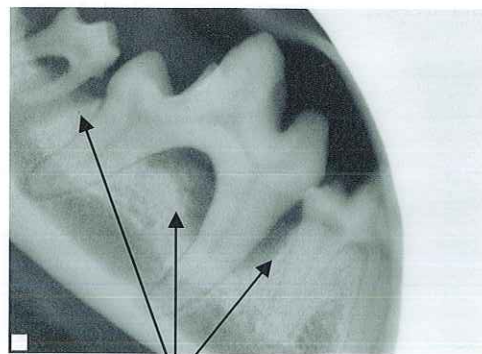


Severe Bone Loss



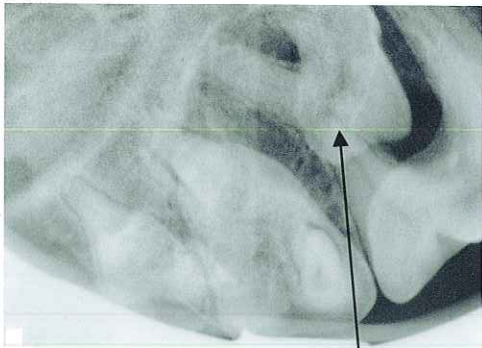
Bone Loss

Abscess

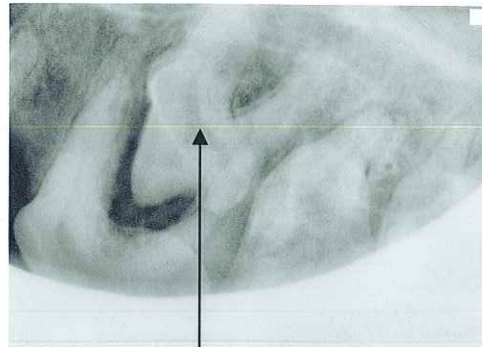


Bone Loss

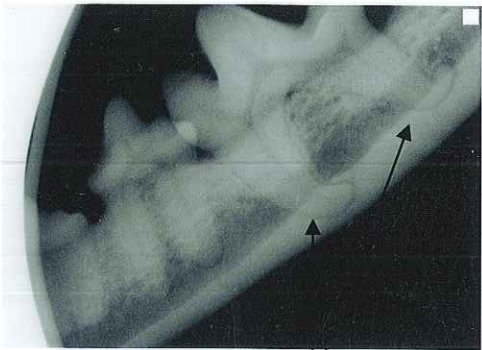
Other Abnormal Findings



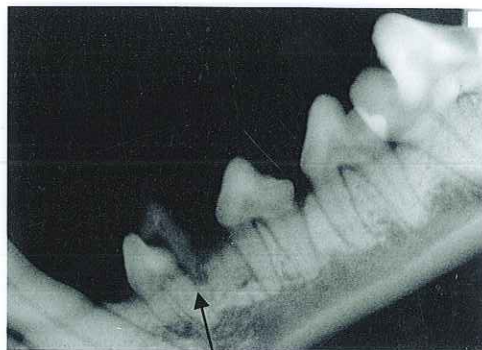
Supernumerary Tooth with Impaction  
(extra)



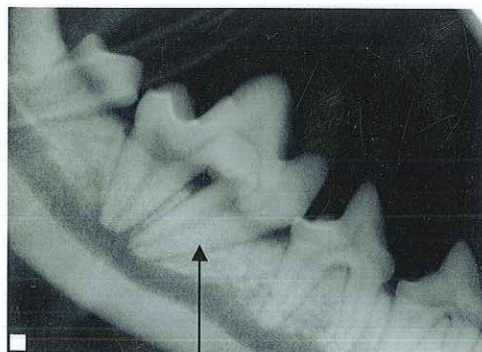
Supernumerary Tooth with Impaction  
(extra)



Hooked Roots



Retained Baby Tooth  
(Gray fragment above tooth)



Abnormal Angled Roots